

Lifetime Toxicity of Chloroform and Bromodichloromethane when Administered over a Lifetime in Rats

CASIMIR F. TUMASONIS, DONALD N. McMARTIN, AND BRIAN BUSH

Division of Laboratories and Research, New York State Department of Health, Albany, New York 12201

Received April 27, 1984

Chloroform (CHCl_3) and bromodichloromethane (CHBrCl_2) are the two most common haloorganic contaminants of chlorinated drinking water. A significantly increased incidence of hepatic neoplastic nodules was found in female rats when each of these compounds was administered in drinking water to Wistar rats throughout their life span. Hepatic adenofibrosis was also produced by chronic ingestion of these two halomethanes. © 1985 Academic Press, Inc.

INTRODUCTION

Chloroform (CHCl_3) and bromodichloromethane (CHBrCl_2) were detected by Bush *et al.* (1977) in 100 and 94%, respectively, of water samples from 29 public water supplies surveyed in New York state. A similar survey of the water of 70 Canadian municipalities showed the presence of CHCl_3 , CHBrCl_2 , chlorodibromomethane (CHBr_2Cl), and bromoform (CHBr_3) (Environmental Health Directorate, 1977). More recently Schreiber (1981) reported on the occurrence of trihalomethane in public water supply systems of New York state. Previous studies (Bellar *et al.*, 1974; Dowty *et al.*, 1975; USEPA, 1975) have also indicated a number of haloorganics to be present in publicly supplied drinking water in other areas of the United States.

Public awareness of the presence of haloorganics in drinking water has been promoted in nontechnical articles (Haber, 1976; Wade, 1977). Concern over the hazards associated with these compounds in public drinking water continues (Gillies, 1978; National Research Council, 1978; Winslow and Gerstner, 1978; Chu *et al.*, 1980; Maugh, 1981).

The chronic toxicity of CHCl_3 has been examined in several studies. In a study conducted by NCI (1976), oral administration of CHCl_3 was concluded to produce hepatomas in mice and renal tumors in male Sprague-Dawley rats. Reuber (1979) independently examined the slides of liver tissues from the same rats and claimed to have found a statistically significant number of hepatic cholangiocarcinomas in the female rats. CHCl_3 , following long-term administration in a toothpaste base, produced renal tumors in mice (Roe *et al.*, 1979), but was not considered to be carcinogenic to Sprague-Dawley rats by Palmer *et al.* (1979). The chronic toxicity of CHBrCl_2 , the second most common haloorganic contaminant of drinking water, has not been examined. In the present study we show that significantly increased incidences of neoplastic nodules were found in livers of female rats ingesting either CHCl_3 or CHBrCl_2 in their drinking water.

MATERIALS AND METHODS

The rats used are of a Wistar stock that has been maintained as a closed colony by this Department. They were maintained in a temperature-controlled room ($21 \pm 2^\circ\text{C}$) with a relative humidity of 50–60%, and 20 air changes per hour. All rats were housed on wood-shavings bedding and were fed (Wayne Lab Blox) and watered *ad libitum*.

Haloorganic treatment was initiated with weanlings at 2 ml (2.9 g) CHCl_3 /liter drinking water (24 mM), or 1.2 ml (2.4 g) CHBrCl_2 /liter drinking water (15 mM). The water used was city drinking water. This concentration was near the maximal level acceptable to the rats. In preliminary studies these concentrations of the haloorganics when administered to 8-week old male and female Wistar rats for 3 weeks failed to produce histologic lesions in their livers, kidneys, or hearts. Concentrations of these halomethanes were halved at 72 weeks after initiation of treatment because of a gradually increasing intake of water by the experimental rats. Water intake was measured weekly, at which time unused portions were replaced with freshly prepared solutions. Concentrations of CHCl_3 (Baker's analyzed) and CHBrCl_2 (Aldrich, analyzed) were measured periodically by the method of Narang and Bush (1980) using gas chromatography with an electron-capture detector. The concentration of the test chemicals remained essentially unchanged while in the rat water bottles for a week's duration.

All rats were identified by ear punching and weighed weekly for the first 24 weeks, biweekly for the next 20 weeks, and thereafter at 4-week intervals.

Rats were killed with diethyl ether or carbon dioxide when judged to be moribund or for humane reasons when a large tumor was noted. Sections of livers from all necropsied rats, and sections from other organs with grossly observable lesions were examined histologically following fixation in 10% buffered Formalin, embedding in paraffin, and staining with hematoxylin and eosin. Severely cannibalized or autolyzed animals were not necropsied. Tumor incidences in the necropsied rats were analyzed statistically by Fisher's exact test and survival curves were drawn using the BMDP computer programs (Brown, 1977).

RESULTS

Growth-weight curves for both sexes of CHCl_3 - and CHBrCl_2 -treated rats and for the untreated controls are shown in Fig. 1. Treated rats weighed less than their controls at all ages. Figures 2 and 3 show the intake of CHCl_3 and CHBrCl_2 , respectively, on a milligram per kilogram body weight basis. From the 5th to the 15–17th week of age, intake of the halomethanes by males and females in each test group were equal. Subsequently females had a higher intake of the halomethanes.

Survival curves of rats with hepatic adenofibrosis and neoplastic nodules are compared to those of all rats necropsied in each of the experimental and control groups (Fig. 4).

Table 1 summarizes the major tumor types found in necropsied rats. The incidence of neoplastic nodules was significantly increased in CHCl_3 - and CHBrCl_2 -treated female rats above the incidence found in control females. Two hepatocellular carcinomas also developed in CHCl_3 -treated rats. This is the first known report associating CHBrCl_2 with carcinogenesis.

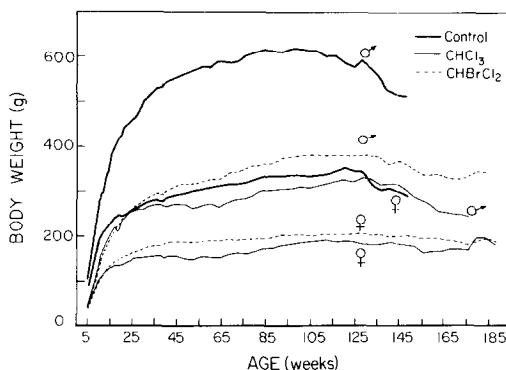


FIG. 1. Average weight gains in Wistar rats ingesting chloroform and bromodichloromethane, and in untreated controls, during their life span.

The incidence of adenofibrosis was significantly increased in CHBrCl₂-treated females and in both sexes of CHCl₃-treated animals above the 0% incidence in controls (Table 1). Macroscopically, adenofibrosis appeared as one or more firm, tan mass replacing part or all of the normal hepatic tissue of one or more of the liver lobes. The masses were either enlarged with a coarsely nodular or shiny surface, or were confined within the liver lobes which retained their original shape. Occasionally, round masses 2 to 8 mm in diameter, with depressed centers were noted as discrete areas in otherwise normal appearing liver. Compensatory hypertrophy of otherwise normal appearing lobes occurred when adenofibrotic lobes were heavily involved.

Microscopically (Fig. 5), areas of adenofibrosis contained groups of acini or cysts often incompletely lined with tall atypical basophilic columnar cells especially on the advancing rim of the lesion. Mitotic figures in these cells varied from 0 to 3 per high-power field. The cysts, and often the acini, were filled with cellular debris or amorphous proteinaceous material. Fibroplasia was also most prominent on the outer edge of the lesion with the centers of large lesions appearing fibrotic and relatively acellular. Other areas containing densely packed acini lined with low

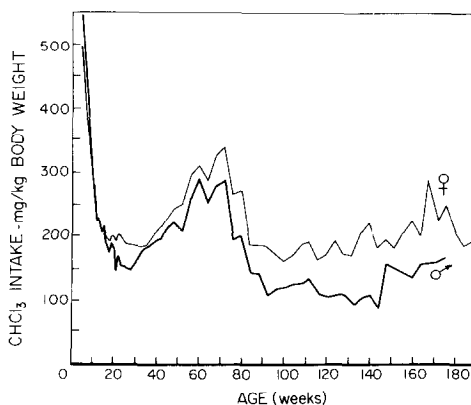


FIG. 2. Intake of CHCl₃ on a mg/kg body wt basis by male and female Wistar rats over their lifespan.

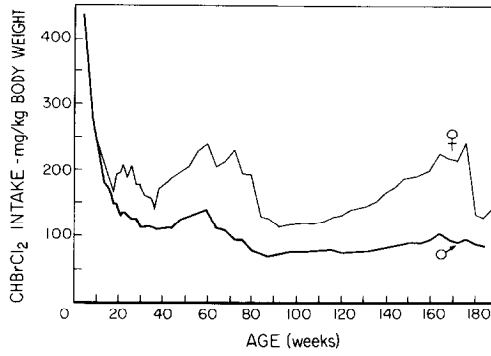


FIG. 3. Intake of CHBrCl_2 on a mg/kg body wt basis by male and female Wistar rats over their lifespan.

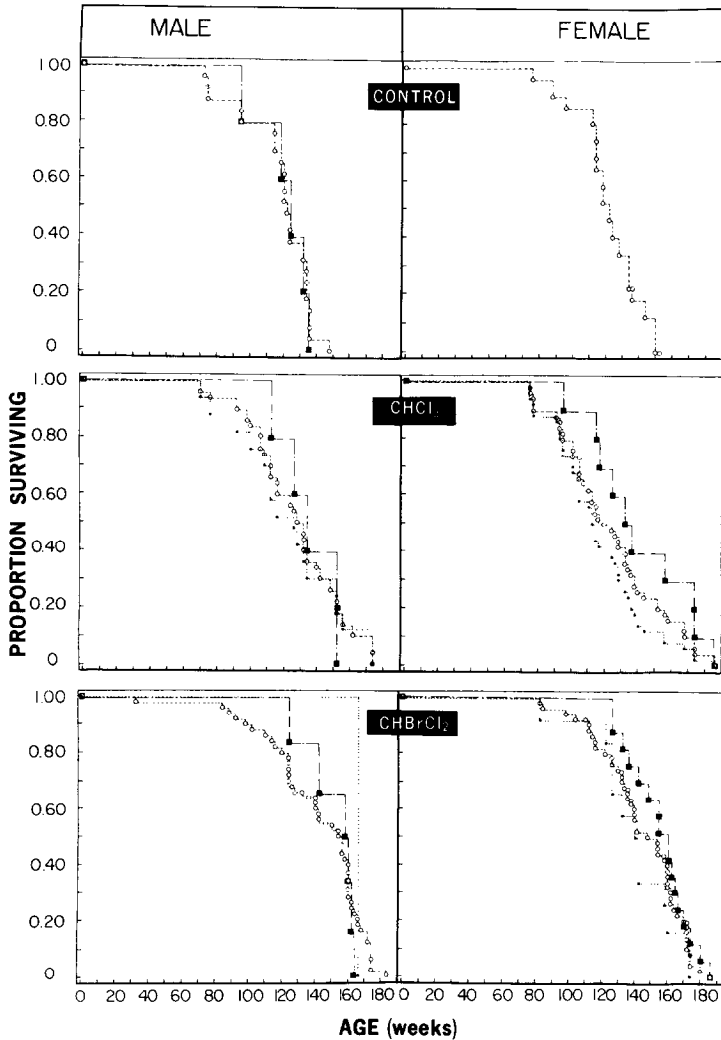


FIG. 4. Survival curves of control and experimental rats with and without neoplastic nodules (■), hepatic adenofibrosis (●); all necropsied rats (○).

TABLE 1
MAJOR TUMORS FOUND IN CONTROL, CHLOROFORM-, AND BROMO-
DICHLOROMETHANE-TREATED RATS

Tumors	Males			Females		
	Control	CHCl ₃	CHBrCl ₂	Control	CHCl ₃	CHBrCl ₂
Neoplastic nodules	5 (23) ^a	5 (18)	6 (13)	0 (0)	10 (25) ^d	17 (32) ^b
Hepatic adenofibrosis	0 (0)	17 (61) ^b	1 (2)	0 (0)	34 (85) ^b	12 (23) ^d
Lymphosarcoma	14 (64)	6 (21) ^c	9 (19) ^b	2 (11)	4 (10)	9 (17) ^c
Pituitary tumor	1 (5)	2 (7)	10 (21)	6 (33)	1 (3) ^c	5 (9) ^d
Mammary tumor	0 (0)	0 (0)	0 (0)	8 (44)	0 (0) ^b	3 (6) ^b
No. rats necropsied	22	28	47	18	40	53
No. rats started	26	32	58	22	45	58

^a Number and percentage () of rats with this tumor. Several rats had two tumors present.

^b $P < 0.001$ compared to control of same sex.

^c $P < 0.01$ compared to control of same sex.

^d $P < 0.03$ compared to control of same sex.

cuboidal epithelium were sometimes present near and occasionally intermingled with the previously described more proliferative lesions.

Table 2 summarizes the various miscellaneous tumors found in necropsied rats after histopathological examination of these lesions. All tumors that have been diagnosed by others as lymphosarcomas, plasma cell lymphomas (M. Bishop, unpublished; Henry and Farrer-Brown, 1977), and reticulum cell sarcomas (Swaen and Van Heerde, 1973) were grouped under the designation "lymphosarcoma." In contrast to the NCI Study on CHCl₃, only a few renal tumors were induced by this halomethane in our rats. One renal adenocarcinoma was found in each of the male and female CHBrCl₂- and one male of the CHCl₃-treated groups, and a renal adenoma appeared in one male CHCl₃-, and one male CHBrCl₂-treated rat (Table 2).

DISCUSSION

CHBrCl₂, the second most commonly reported contaminant of chlorinated drinking water (Bush *et al.*, 1977) was shown to be carcinogenic to rats ingesting it in their drinking water. This is the first known report of the neoplasmogenic ability of CHBrCl₂. Both this compound and CHCl₃, which was used as a positive control, produced intrahepatic lesions.

The production of neoplastic nodules in our rats ingesting CHCl₃ also adds support to other studies (Eschenbrenner, 1945; National Cancer Institute, 1976; Palmer *et al.*, 1979) demonstrating the carcinogenicity of CHCl₃. This is of special interest in view of an epidemiological study (Hogan *et al.*, 1979) showing the possible association between incidences of certain human cancers and CHCl₃ levels in drinking water. CHCl₃ may have other adverse effects related to cancer. Capel *et*

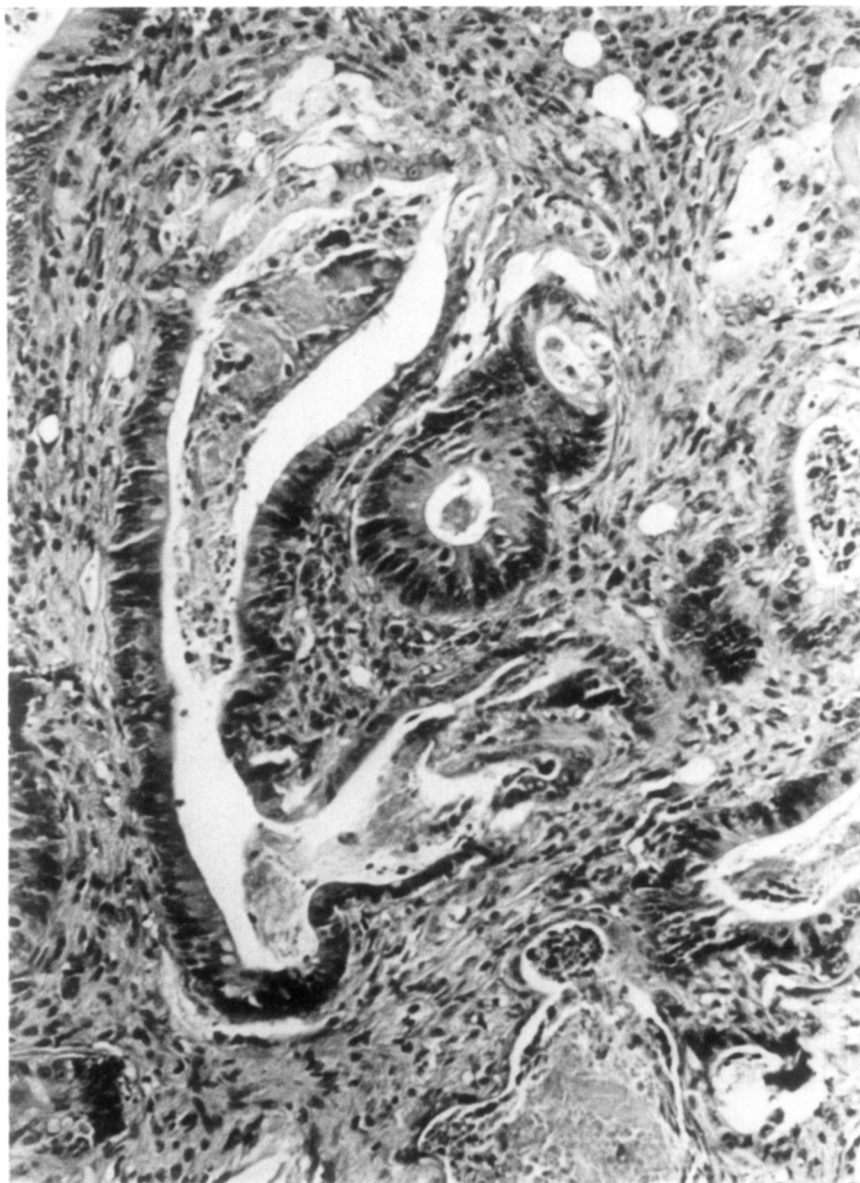


FIG. 5. Outer edge of an area of adenofibrosis. Debris-filled cysts are lined by tall basophilic cells and are surrounded by fibroplastic tissue. Hematoxylin and eosin, $\times 80$.

al. (1979) found that certain experimental tumors grew faster and metastasized more often in mice drinking CHCl_3 -containing water.

Induction of hepatic lesions vs other tumor types (e.g., renal carcinomas) as in the NCI study may be related to the genetic makeup of our Wistar rats, or to the route of exposure to the haloorganics. We feel that administration of these compounds in drinking water is a more natural method than gavage since such voluntary intake results in lower and more prolonged blood and liver haloorganic concentrations.

TABLE 2

MISCELLANEOUS TUMORS FOUND IN NECROPSIED CONTROL AND EXPERIMENTAL RATS

Tumor	Controls		CHCl ₃		CHBrCl ₂	
	M	F	M	F	M	F
Hepatocellular carcinoma			1	1		
Hemangioma	1		1	1		2
Hemangiosarcoma	2			1		
Renal adenoma			1		1	
Renal adenocarcinoma			1		1	1
Fibroma	2	2			2	
Fibrosarcoma					1	4
Lipoma	1					
Keratoacanthoma					3	1
Squamous cell carcinoma					1	2
Adrenal cortical adenoma	1					1
Adrenal cortical carcinoma	1				1	
Adrenal pheochromocytoma						1
Islet cell adenoma	1			1		
Islet cell carcinoma					1	
Thyroid adenoma						1
Rhabdomyosarcoma			1			
Leiomyoma					1	
Leiomyosarcoma		1				
Mesothelioma	1		2		3	
Prostatic carcinoma					1	
Glioblastoma					1	
Oligodendroglioma						1
Astrocytoma					1	
Neurofibroma	1				1	
Meningioma					1	

Our use of "adenofibrosis" as a diagnostic term is a conservative one and is based on the classification proposed by the Institute of Laboratory Animal Resources of the National Academy of Sciences (1980). This report expressed doubt that "bile duct cells in the rat give rise to adenomatous tumors, i.e., cholangiocarcinomas." Terao and Nakano (1974) suggested that this proliferative lesion of bile ducts, which has been produced by several hepatocarcinogens, may not be merely reactive but may possess the autonomous properties of a tumor. Indeed, Schauer and Kunze (1976) in their chapter on rat liver tumors designated lesions similar to those in our rats as cholangiocellular carcinomas.

Our findings of the carcinogenicity of CHCl₃ and CHBrCl₂, two common contaminants of chlorinated drinking water, should provide further impetus to more fully evaluate the relative risks of different methods of water purification, especially of publicly supplied water.

ACKNOWLEDGMENTS

The authors acknowledge the assistance of Ms. Patricia Abdo and Maria Mahar in the handling and care of animals; Dr. T. Turriel for statistical advice; and Dr. L. S. Kaminsky for reading of the manuscript and helpful comments.

REFERENCES

- BELLAR, T. A., LICHTENBERG, J. J., AND KRONER, R. C. (1974). The occurrence of organohalides in chlorinated drinking water. *J. Amer. Water Works Assoc.* **66**(12), 703-706.
- BROWN, M. B. (1977). *BMDP Biomedical Computer Program P-Series*. Univ. of California Press.
- BUSH, B., NARANG, R. S., AND SYROTYNSKI, S. (1977). Screening for haloorganics in New York State drinking water. *Bull. Environ. Contam. Toxicol.* **18**, 436-441.
- CAPEL, I. D., DORRELL, H. M., JENNER, M., PINNOCK, M. H., AND WILLIAMS, D. C. (1979). The effects of chloroform ingestion on the growth of some murine tumors. *Eur. J. Cancer* **15**, 1485-1490.
- CHU, I., SECOURS, V., MARINO, I., AND VILLENUEVE, D. C. (1980). The acute toxicity of four halomethanes in male and female rats. *Toxicol. Appl. Pharmacol.* **52**, 351-353.
- DOWTY, B., CARLISLE, D., LASETER, J. L., AND STORER, J. (1975). Halogenated hydrocarbons in New Orleans drinking water and blood plasma. *Science (Washington, D.C.)* **187**, 75-77.
- Environmental Health Directorate, Health Protection Branch, Health and Welfare. (1977). *National Survey for Halomethanes in Drinking Water*. 77-EDH-9. Canada.
- ESCHENBRENNER, A. B. (1945). Induction of hepatomas in mice by repeated oral administration of chloroform, with observations on sex differences. *J. Natl. Cancer Inst.* **5**, 251-255.
- GILLIES, M. T. (1978). Statement of basis and purpose for the amendment on trihalomethanes. In *Drinking Water Detoxification* (M. T. Gillies, ed.), pp. 86-125. Noyes Data Corp., Park Ridge, New Jersey.
- HABER, G. (1976). Organic chemicals in drinking water. *Sciences (New York)* **16**, 23-26.
- HENRY, K., AND FARRER-BROWN, G. (1977). Primary lymphomas of the gastrointestinal tract. I. Plasma cell tumours. *Histopathology* **1**, 53-76.
- HOGAN, M. D., CHI, P.-Y., AND HOEL, D. G. (1979). Association between chloroform levels in finished drinking water supplies and various site-specific cancer mortality rates. *J. Environ. Pathol. Toxicol.* **2**, 873-887.
- Institute of laboratory animal resources. Histologic typing of liver tumours of the rat. *J. Natl. Cancer Inst.* **64**, 179-206.
- MAUGH, T. H., II. (1981). New study links chlorination and cancer. *Science (Washington, D.C.)* **211**, 694.
- NARANG, R. S., AND BUSH, B. (1980). Determination of arenes, vinyl chloride, and other volatile haloorganic compounds in water at microgram-per-liter levels by gas chromatography. *Anal. Chem.* **52**, 2076-2079.
- National Cancer Institute. (1976). *NCI Report on the Carcinogenesis Bioassay of Chloroform*. March 1, Washington D.C.
- National Research Council. (1978). Chloroform, carbon tetrachloride and other halomethanes: An environmental assessment. Natl. Acad. of Sci., Washington, D.C.
- PALMER, A.K., STREET, A. E., ROE, F. S. C., WORDEN, A. N., AND VANABBE, N. J. (1979). Safety evaluation of toothpaste containing chloroform. II. Long term studies in rats. *J. Environ. Pathol. Toxicol.* **2**(3), 821-833.
- REUBER, M. D. (1979). Carcinogenicity of chloroform. *Environ. Health Perspect.* **31**, 171-182.
- ROE, E. J., PALMER, A. K., WORDEN, A. N., AND VANABBE, N. J. (1979). Safety evaluation of toothpaste containing chloroform. I. Long term studies in mice. *J. Environ. Pathol. Toxicol.* **2**(3), 799-819.
- SCHAUER, A., AND KUNZE, F. (1976). Tumours of the liver. In *Pathology of Tumours in Laboratory Animals* (V. S. Turosov, ed.), Vol. 1, Part 2, pp. 41-72. International Agency for Research on Cancer, IARC Scientific Publication No. 6, Lyons.
- SCHREIBER, J. S. (1981). The occurrence of trihalomethanes in public water supply systems of New York State. *J. Amer. Water Works Assoc.* **73**(3), 1554-159.
- SWAEN, G. J. V., AND VAN HEERDE, P. (1973). Tumours of the haematopoietic system. In *Pathology of Tumours in Laboratory Animals* (V. S. Turosov, ed.), Vol. 1, Part 1, pp. 185-201. International Agency for Research on Cancer, IARC Scientific Publication No. 5, Lyons.
- TERAO, K., AND NAKANO, M. (1974). Cholangiofibrosis induced by short-term feeding of 3'-methyl-4-(dimethylamino)azobenzene: An electron microscopic observation. *Gann* **65**, 249-260.
- US Environmental Protection Agency. (1975). *National Organic Reconnaissance Survey for Halogenated Organics in Drinking Water*. April. Cincinnati.
- WADE, N. (1977). Drinking water health hazards still not resolved. *Science (Washington, D.C.)* **196**, 1421-1422.
- WINSLOW, S. G., AND GERSTNER, H. B. (1978). Health aspects of chloroform—A review. *Drug Chem. Toxicol.* **1**(3), 259-275.